

Clinicopathological and Preclinical Findings of NUT Carcinoma: A Multicenter Study

MINSUN JUNG^{Ⓛ, a, †} SOYEON KIM^{Ⓛ, e, f, †} JUNE-KOO LEE^h SUN OCH YOONⁱ HEAE SURNG PARK^j SOON WON HONG^j WEON-SEO PARK^k Ji EUN KIM^l JOON KIM^h BHUMSUK KEAM^{Ⓛ, b, e} HYUN JIK KIM^{Ⓛ, d} HYOUNG JIN KANG^{c, e} DONG-WAN KIM^{b, e} KYEONG CHEON JUNG^a YOUNG TAE KIM^{e, g} DAE SEOG HEO^{b, e} TAE MIN KIM^{b, e} YOON KYUNG JEON^{Ⓛ, a, e}

Departments of ^aPathology and ^bInternal Medicine, Seoul National University Hospital, ^cDepartment of Pediatrics, Seoul National University Children's Hospital, and ^dDepartment of Otorhinolaryngology, Seoul National University College of Medicine, Seoul, Republic of Korea; ^eSeoul National University Cancer Research Institute, Seoul, Republic of Korea; ^fBiomedical Research Institute and ^gDepartment of Thoracic and Cardiovascular Surgery, Seoul National University Hospital, Seoul, Republic of Korea; ^hGraduate School of Medical Science and Engineering, Korea Advanced Institute of Science and Technology, Daejeon, Republic of Korea; ⁱDepartment of Pathology, Yonsei University College of Medicine, Seoul, Republic of Korea; ^jDepartment of Pathology, Gangnam Severance Hospital, Yonsei University College of Medicine, Seoul, Republic of Korea; ^kDepartment of Pathology, Center for Prostate Cancer, National Cancer Center, Goyang, Republic of Korea; ^lDepartment of Pathology, Seoul Metropolitan Government-Seoul National University Boramae Medical Center, Seoul, Republic of Korea

[†]Contributed equally

Disclosures of potential conflicts of interest may be found at the end of this article.

Key Words. NUT carcinoma • Treatment outcome • MYC-targeting agents • BET inhibitor • HDAC inhibitor

ABSTRACT

Background. NUT carcinoma is a rare aggressive disease caused by *BRD4/3-NUT* fusion, and *C-MYC* upregulation plays a key role in the pathogenesis. Here, we report on the clinicopathological characteristics of Korean patients with NUT carcinoma and the in vitro efficacy of MYC-targeting agents against patient-derived NUT carcinoma cell lines.

Materials and Methods. Thirteen patients with NUT carcinoma were evaluated for p53, C-MYC, epidermal growth factor receptor (EGFR), HER2, and programmed cell death ligand 1 (PD-L1) by immunohistochemistry. The half maximal inhibitory concentration (IC₅₀) values of NUT carcinoma cell lines (SNU-2972-1, SNU-3178S, HCC2429, and Ty-82) were determined using MYC-targeting agents, including bromodomain and extraterminal (BET) inhibitors (I-BET, OTX-015, AZD5153) and histone deacetylase (HDAC) inhibitors (vorinostat, romidepsin, panobinostat, CUDC-907).

Results. Primary tumor sites included head and neck (*n* = 9) and lung (*n* = 4). The patient age ranged from 8 to 73 years with the male/female ratio of 1.2:1. Nine patients died at 3–23.6 months (median, 10.6) after diagnosis. Eight patients

had been misdiagnosed initially with other diseases. One patient with metastatic NUT carcinoma who received mass excision plus metastasectomy followed by chemoradiotherapy was a long-term survivor (>27 months). Although expressions of C-MYC (8/12, 73%) and p53 (12/12, 100%) were commonly observed, EGFR, HER2, and PD-L1 expressions were observed in 2 of 7 (29%), 2 of 8 (25%), and 1 of 12 (8.3%) patients, respectively. BET and HDAC inhibitors showed variable but limited in vitro efficacy. However, a dual HDAC/PI3K inhibitor, CUDC-907, was most potent against NUT carcinoma cells, with an IC₅₀ of 5.5–9.0 pmol/L. Consistent with these findings, kinome short interfering RNA screening showed a positive hit for *PI3KCA* in NUT carcinoma cells. Panobinostat (IC₅₀, 0.4–1.3 nmol/L) and a bivalent BET inhibitor, AZD5153 (IC₅₀, 3.7–8.2 nmol/L), also showed remarkable efficacies.

Conclusion. East Asian patients with NUT carcinoma showed dismal survival outcomes like Western patients, and CUDC-907 might be promising in NUT carcinoma treatment. *The Oncologist* 2019;24:e740–e748

Implications for Practice: NUT carcinoma (NC) is a disease caused by *BRD-NUT* fusion leading to *C-MYC* upregulation. NC is often misdiagnosed and very aggressive, requiring development of effective therapeutic strategy. This article presents the clinicopathological features of the largest series of NCs in East Asians and preclinical sensitivities to MYC-targeting agents in NC cell lines. Patients with NC had grave outcomes and poor response to treatment. Among MYC-targeting agents,

Correspondence: Tae Min Kim, M.D., Ph.D., Department of Internal Medicine, Seoul National University Hospital, 101 Daehak-ro, Jongno-gu, Seoul 03080, Republic of Korea. Telephone: 82-2-2072-3559; e-mail: gabriel9@snu.ac.kr; or Yoon Kyung Jeon, M.D., Ph.D., Department of Pathology, Seoul National University College of Medicine, 103 Daehak-ro, Jongno-gu, Seoul 03080, Republic of Korea. Telephone: 82-2-740-8323; e-mail: ykjeon@snu.ac.kr Received August 6, 2018; accepted for publication November 7, 2018; published Online First on January 29, 2019. <http://dx.doi.org/10.1634/theoncologist.2018-0477>

including BET and HDAC inhibitors, CUDC-907 (a dual PI3K/HDAC inhibitor) was most effective against NC cells, followed by panobinostat (an HDAC inhibitor) and AZD5153 (a bivalent BET inhibitor). CUDC-907 might be promising in NC treatment.

INTRODUCTION

NUT carcinoma is a rare but aggressive disease first described in 1991 as thymic carcinoma in young adults harboring the novel translocation t(15;19)(q15;p13) [1]. *BRD4-NUT* was identified as a major fusion transcript involving *NUT* on chromosome 15q14 and *BRD4* on chromosome 19p13 [2]. Thereafter, several variants of rearrangement, including *BRD3-NUT*, *NSD3-NUT*, and *ZNF532-NUT*, have been reported [3–5]. Although NUT carcinoma was initially reported in children and young adults, the age distribution has been wide (0–78 years) [6, 7]. The predilection midline sites of NUT carcinoma include the head and neck, the thorax, the salivary gland, and other rare locations (testis, bladder, and thyroid) [7, 8]. Histologically, NUT carcinoma shows sheets or nests of undifferentiated tumor cells with or without abrupt squamous differentiation [9]. Therefore, NUT carcinoma is often misdiagnosed as undifferentiated carcinoma or poorly differentiated squamous cell carcinoma [9].

Standard treatment for NUT carcinoma has not been well established. Although local approaches, including complete resection of the tumor and initial radiotherapy, significantly improved the survival of patients with NUT carcinoma [7, 8], their use is not always possible because of locally advanced or metastatic disease [7]. The clinical outcomes of chemotherapy and radiotherapy were variable across several studies [7, 8, 10]. Despite multimodal treatments, the survival outcome is generally dismal (median overall survival, 4.7–9.7 months) [6–8, 10]. The pathophysiology of NUT carcinoma depends on *NUT* translocation, which mostly transcribes *BRD4-NUT* fusion protein binding to chromatin via the bromodomain, forming a transcriptionally active domain by recruiting histone acetyltransferase (HAT) and transcription factors, activating certain oncogenes (e.g., *C-MYC*), and leading to dysregulation of normal differentiation [5, 11–14]. Therefore, many researchers have focused on targeted agents, including the bromodomain and extraterminal (BET) and histone deacetylase (HDAC) inhibitors [12, 15]. Both inhibitor types were demonstrated to abrogate dysregulated growth and induce squamous differentiation of NUT carcinoma *in vitro* and *in vivo*, which are translated into clinical activities [12, 16, 17].

In this study, we assessed clinicopathological features and treatment outcomes of 13 patients diagnosed with NUT carcinoma in multiple Korean centers. We also compared the *in vitro* efficacy of MYC-targeting agents against patient-derived NUT carcinoma cell lines.

MATERIALS AND METHODS

Patients

A total of 13 patients with NUT carcinoma from Seoul National University Hospital, Severance Hospital, Gangnam Severance Hospital, and Seoul Metropolitan Government-Seoul National University Boramae Medical Center, Korea, were included in this study (Table 1). Tissue samples from

one patient (NUT carcinoma [NC] 2) were obtained from the Human Tissue Bank of Gangnam Severance Hospital, Yonsei University College of Medicine (no. HTB-P2017-19). Four cases (NC2–5) were reported previously [18–20]. Clinical data, including tumor location, initial symptoms, stage, and treatment outcomes, were obtained from medical records. Response assessment was performed using RECIST 1.1 [21]. Progression-free survival (PFS) was calculated from the date of initial treatment to the date of whichever came first among progression, relapse, death, and last follow-up visit. Overall survival (OS) was measured from the date of initial diagnosis to the date of death or last follow-up visit, with a cutoff in January 2018. Survival was analyzed with Kaplan-Meier plots and the log-rank test using IBM SPSS statistics 24 software (IBM; Armonk, NY). TNM classification was based on the 7th edition of the American Joint Committee on Cancer's cancer staging. The present study was approved by the Institutional Review Board of Seoul National University Hospital (no. 1706-059-859).

Histological Examination and Immunohistochemistry

Experienced pathologists at each hospital reviewed the pathological materials, including hematoxylin and eosin-stained and NUT immunohistochemistry (IHC) slides. Two pathologists (M.J., Y.K.J.) reviewed all pathological slides. IHC was performed on formalin-fixed paraffin-embedded (FFPE) tissue using the following antibodies: monoclonal rabbit antibodies against NUT (clone C52B1; Cell Signaling Technology; Danvers, MA); C-MYC (clone EP121 [also known as clone Y69]; Cell Marque; Rocklin, CA), synaptophysin (clone Z66; Invitrogen; Carlsbad, CA), HER2/neu (clone 4B5; Ventana, Tucson, AZ), and programmed cell death ligand 1 (PD-L1; clone E1L3N; Cell Signaling Technology); and monoclonal mouse antibodies against p63 (clone A4A; Ventana); CD56 (clone 123C3; Invitrogen), chromogranin (clone 5H7; Leica Biosystems; Wetzlar, Germany), p53 (clone DO-7; Dako; Glostrup, Denmark), epidermal growth factor receptor (EGFR; clone 3C6; Ventana), cytokeratin (clone AE1/AE3; Dako), CK5/6 (clone D5/16 B4; Dako), CK19 (clone RCK108; Dako), and CK20 (clone Ks 20.8; Dako). IHC was performed using the BenchMark autostainer (Ventana) with appropriate control tissue on every slide. NUT staining was interpreted as positive when most (>50%) tumor cells showed distinct nuclear expression of NUT [22].

Fluorescence In Situ Hybridization

Interphase fluorescence *in situ* hybridization (FISH) was performed for every collected case on 3- μ m-thick FFPE tissue using the ZytoLight SPEC NUTM1 dual color break-apart probe (PL166, ZytoVision; Bremerhaven, Germany) to detect translocation involving the *NUT* gene according to the manufacturer's instructions. After counterstaining of the nuclei, the slides were examined using Allegro Plus with a Solo

Table 1. Clinical features and treatment outcomes of patients with NUT carcinoma

No.	Age/ sex	Site	Size, cm	Stage				Initial Sx	Onset, wk	Tx detail	Upfront CT Rx	Op extent	CT/RT response	Tx failure ^a	Outcome	PFS, mo	OS, mo
				T	N	M	TNM										
NC1	8/M	Maxillary sinus	5.1	4a	0	0	IVA	Nasal obstruction	2	CT→Op→CCRT→CT	FP + Bleomycin	R2	SD	Sys	Death	12	16.4
NC2 [20]	12/M	Parotid gland	4.0	3	2b	0	IVA	Parotid mass	n.a.	Op→CCRT	IFO	R1	PD	LR	Death	4.6	23.6
NC3 [19]	29/F	SMG	1.5	1	2a	1	IVC	Neck mass	4	Op→CT→RT	DP	R0	n.a.	None	NED	27	27
NC4 [18]	33/F	Lung	9.8	4	3	1b	IV	Chest pain	4	CCRT	TC	None	PR	Both	Death	5.2	7.9
NC5 [18]	34/M	Lung	9.6	3	3	1b	IV	Dyspnea	2	CT	TC	None	PR	Both	Death	2.2	3.8
NC6	47/M	Nasal cavity	n.a.	4b	0	0	IVA	Headache	4	CCRT→Op→CCRT	CDDP	R1	PD	LR	Death	3.8	9.3
NC7	48/F	Nasal cavity	3.5	4a	0	0	IVA	Epistaxis	2	Op→CCRT→CT→Op	CDDP	R2	PR	LR	Death	7.0	18.7
NC8	51/M	Nasal cavity	5.7	4a	0	0	IVA	Epistaxis	20	CT→Op→CCRT	DFP	R2	PD	LR	Death	1.5	10.6
NC9	59/F	Maxillary sinus	3.5	4a	2b	0	IVA	Maxillary pain	4	CCRT	CDDP	None	PD	Both	Death	2.6	3.0
NC10	64/M	Nasal cavity	4.7	4a	0	0	IVA	Headache	2	Op→CCRT→CT	CDDP	R2	PR	Sys	Death	5.6	8.2
NC11	66/F	Nasal cavity	6.1	3	0	0	III	Nasal obstruction	8	n.a.	n.a.	n.a.	n.a.	n.a.	AOD	n.a.	11.4
NC12	68/M	Lung	6.1	2b	1	0	IIB	Hemoptysis	3	Op→CT	GC	R0	n.a.	LR	AOD	1.4	2.8
NC13	73/F	Lung	2.5	2a	0	0	IIA	Cough	4	Op→BETi→RT	None	R0	n.a.	LR	AOD	4.4	9.7

^aTreatment failure type: LR, locoregional; Sys, systemic; Both, locoregional and systemic.

Abbreviations: AOD, alive on disease; BETi, bromodomain and extraterminal inhibitor; CCRT, concurrent chemoradiotherapy; CDDP, cisplatin; CT, chemotherapy; DFP, docetaxel, 5-FU, and cisplatin; DP, docetaxel and cisplatin; F, female; FP, 5-FU and cisplatin; GC, gemcitabine and carboplatin; IFO, ifosfamide; M, male; n.a., not available; NC, NUT carcinoma; NED, no evidence of disease; No. number of patient; Op, operation; OS, overall survival; PD, progression of disease; PFS, progression-free survival; PR, partial remission; RT, radiotherapy; Rx, regimen; SD, stable disease; SMG, submandibular gland; Sx, symptom; TC, docetaxel and cyclophosphamide; Tx, treatment.

Touch Workstation (BioView Ltd.; Rehovot, Israel) and reviewed manually by pathologists (M.J., Y.K.J.) under an Olympus BX51TRF microscope (Olympus Corporation; Tokyo, Japan) equipped with the appropriate filters. NUT FISH results were interpreted as positive as described previously [22].

Kinome Short Interfering RNA Screening

SNU-2972-1 and SNU-3178S cells that had been established from patients with NC4 and NC5, respectively [18], were seeded at a density of 10,000 cells per well (384-well plates). Four different short interfering RNAs (siRNAs) targeting human protein kinases (Dharmacon; Lafayette, CO) were transfected into cells with final concentrations of 15 nM (3.75 nM each, pooled) using lipofectamine RNAi-Max reagent (Life Technologies; Carlsbad, CA). Transfected cells were incubated for 84 h, and the Cell Counting Kit-8 assay (Dojindo; Kumamoto, Japan) was performed according to the manufacturer's protocol.

Cell Culture, Reagents, and Cell Proliferation

SNU-2972-1 and SNU-3178S cell lines were obtained from the Korean Cell Line Bank, and Ty-82 cells were purchased from the JCRB Cell Bank. The HCC2429 cell line was provided by Matthew Meyerson (Dana-Farber Cancer Institute; Boston, MA). SNU-3178S cells harbored *BRD3-NUT* fusion and SNU-2972-1, Ty-82, and HCC2429 cells had *BRD4-NUT* fusion [18]. All cells were maintained in RPMI 1640 medium supplemented with 10% Fetal bovine serum (Gibco by Life Technologies) and 1% penicillin-streptomycin in a humid environment of 5% CO₂ at 37°C.

CUDC-907, panobinostat, vorinostat, romidepsin, I-BET, OTX-015, and AZD5153 were purchased from Selleckchem (Houston, TX). Cells were seeded in 96-well plates at 1×10^4

with vehicle (0.1% dimethyl sulfoxide) or increasing concentrations of drugs from 0.01 nmol/L to 10,000 nmol/L for 72 h. To detect viability, the Cell Titer-glo reagent (Promega; Madison, WI) was added according to the manufacturer's instructions. The plates were read using a luminescence microplate reader (Promega). GraphPad Prism 5.0 (GraphPad Software, La Jolla, CA) was used for curve fitting, and SigmaPlot was used for calculation of the half maximal inhibitory concentration (IC₅₀). Two or three independent experiments with duplicates were performed for each experiment.

RESULTS

Clinical Features

The clinical features and treatment outcomes of the 13 patients with NUT carcinoma are summarized in Table 1, and representative features of NC3 and 13 patients are shown in Figure 1. Nine cases occurred in the head and/or neck, including the sinonasal area ($n = 7$) and salivary gland ($n = 2$), and four were of pulmonary origin. The male/female ratio was 1.2:1, and the median age was 48.0 years (range, 8-73). Initial symptoms included dyspnea, chest pain, cough, and hemoptysis for pulmonary NUT carcinoma cases and epistaxis, headache, and nasal obstruction for the head and/or neck cases, with short onset times (within 2-4 weeks in most patients). The mean (\pm SD) main tumor diameter at diagnosis was 5.2 (\pm 2.4) cm. Lymph node involvement and distant metastasis were observed in six (46%) and three (23%) patients, respectively. The sites of distant metastasis included the bone, pleura, and adrenal gland. All patients except NC12 and 13 presented with advanced stage (III/IV; stage IV, $n = 10$) disease (Table 1).

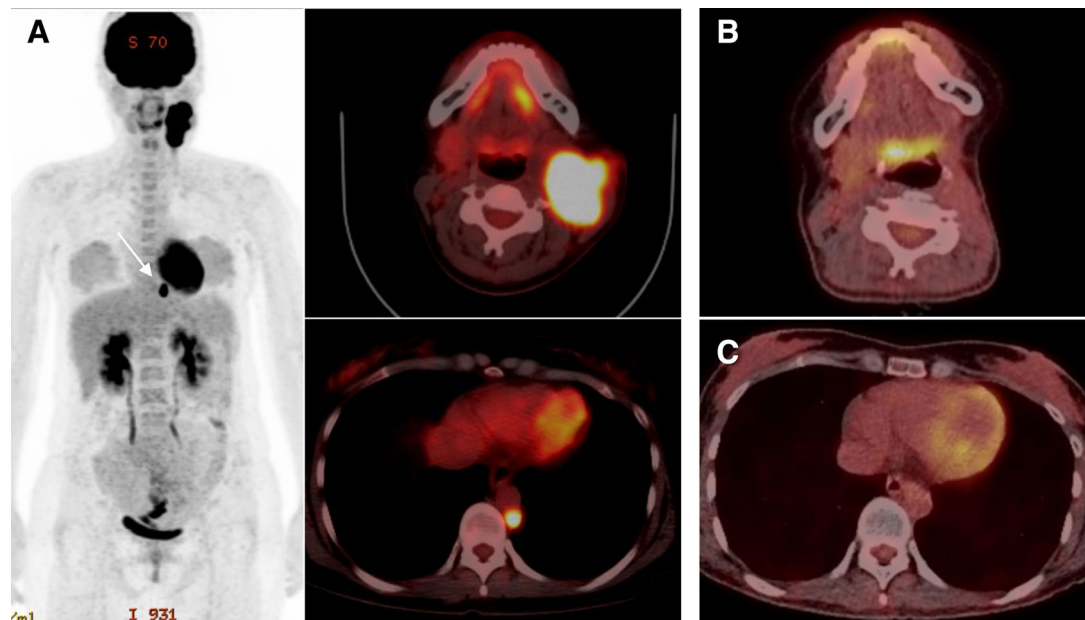


Figure 1. Radiological features of patients NUT carcinoma (NC) 3. **(A):** An initial positron emission tomography (PET)/computed tomography (CT) scan showed hypermetabolic lesions located in the left submandibular gland area and para-aortic lymph node (white arrow). After gross total resection of the primary and metastatic tumors, followed by adjuvant chemotherapy and radiotherapy, no evidence of remaining tumor was detected in the neck **(B)** or para-aortic area **(C)**.

Treatment Outcomes

Therapeutic options were selected at the clinicians' discretion, and detailed information was available for 12 patients (Table 1). Six (50%) patients underwent initial surgery, whereas the other six received upfront chemotherapy ($n = 3$) or concurrent chemoradiotherapy ($n = 3$); for four patients, surgery was performed subsequently. The overall response to upfront chemotherapy or chemoradiotherapy was evaluable in nine patients, among whom four (44%) had partial responses and one had stable disease. However, 11 patients experienced relapse or disease progression, and 9 died of the disease. The median PFS and OS were 4.4 (range, 1.4-12) and 10.6 (range, 3.0-23.6) months, respectively. Locoregional failure was observed in nine patients, including three with concomitant systemic failure. By contrast, systemic failure without local recurrence was observed in two patients. Initial surgery ($n = 6$) was related to longer OS by the log-rank test ($p = .017$). One long-term survivor, NC3, was a 29-year-old woman with a submandibular gland tumor and distant metastasis in the para-aortic lymph node (Fig. 1A). She underwent submandibular gland resection with modified radical neck dissection plus dissection of the para-aortic lymph node. Thereafter, she received six cycles of docetaxel plus cisplatin followed by consolidation radiotherapy and has been alive without disease for 27 months (Fig. 1B, 1C).

Pathological Findings

Histopathological features are summarized in Table 2, and representative images are shown in Figure 2. Eight patients were initially diagnosed with a disease other than NUT carcinoma, including poorly differentiated squamous cell carcinoma ($n = 3$), sinonasal undifferentiated carcinoma ($n = 4$), and mucoepidermoid carcinoma ($n = 1$). NUT carcinoma

tumors were composed of medium-sized, poorly differentiated cells showing numerous mitoses (Fig. 2A, 2G). Abrupt keratinization was observed frequently in NC13 (Fig. 2G, 2J) and NC3. The nuclei of most tumor cells showed NUT immunostaining, with a speckled pattern in all cases except NC7, which showed focal NUT expression (Table 2; Fig. 2B, 2H). *NUT* translocation was confirmed in all cases using FISH (Fig. 2F, 2O). In NC13, tumor cells harboring three copies of the *NUT* gene, including one isolated red signal, were occasionally observed in addition to a typical split pattern of the *NUT* gene (Fig. 2O). Cytokeratin and p63 expression was observed in nine of nine and six of eight cases, respectively (Fig. 2E, Table 2). p53 and C-MYC immunostaining was observed in all (12/12) and 67% (8/12) of evaluated cases, respectively, in a diffuse or focal pattern (Fig. 2C, 2D, 2L). Of note, the expression levels of NUT and C-MYC were decreased in keratinized cells (Fig. 2L). EGFR and HER2 expressions were observed in 29% (2/7) and 25% (2/8) of evaluable cases, respectively (supplemental online Fig. 1A-C). PD-L1 expression was observed in only 1 (NC6) of the 12 evaluated cases whose tissue was obtained after concurrent chemoradiotherapy (supplemental online Fig. 1D).

In Vitro Sensitivity Study of BET and HDAC Inhibitors

We investigated the effect of targeted inhibitor treatment on cell proliferation using four cancer cell lines harboring *BRD-NUT* gene translocation. Treatment with the monovalent BET inhibitors, I-BET and OTX-015, and HDAC inhibitors, vorinostat and romidepsin, had a moderate or little effect on NUT carcinoma cell viability. However, treatment with the HDAC inhibitors, CUDC-907 and panobinostat, and a bivalent BET inhibitor, AZD5153, resulted in growth inhibition in a

Table 2. Pathological findings in patients with NUT carcinoma

No.	Initial diagnosis	NUT		Immunohistochemistry								
		IHC	FISH	Keratin ^a	p63	NE ^b	p53 ^c	C-MYC ^c	EGFR	HER2	PD-L1	
NC1	SNUD	P	P	P	N	N	P (75%)	N	N	N	N	
NC2 [20]	MEC	P	P	P	P	N	Focal P (30%)	N	n.a.	n.a.	N	
NC3 [19]	NC	P	P	P	P	N	P (85%)	P (80%)	n.a.	P (80%)	N	
NC4 [18]	NC	P	P	n.a.	P	n.a.	P (85%)	Focal P (30%)	n.a.	n.a.	N	
NC5 [18]	NC	P	P	P	Focal P	N	P (80%)	Focal P (40%)	n.a.	n.a.	N	
NC6	SNUD	P	P	n.a.	n.a.	n.a.	P (50%)	Focal P (20%)	n.a.	n.a.	P (10%)	
NC7	SNUD	Focal P (10%)	P	P	N	N	P (60%)	N	N	N	N	
NC8	SqCC	P	P	P	P	n.a.	P (85%)	Focal P (10%)	P (30%)	N	N	
NC9	SNUD	P	P	P	n.a.	N	P (70%)	Focal P (20%)	N	N	N	
NC10	NC	P	P	P	n.a.	N	P (70%)	P (70%)	N	N	N	
NC11	NC	P	P	n.a.	n.a.	n.a.	n.a.	n.a.	n.a.	n.a.	n.a.	
NC12	SqCC	P	P	P	P	N	P (60%)	N	N	N	N	
NC13	SqCC	P	P	n.a.	n.a.	N	P (60%)	Focal P (30%)	P (40%)	P (10%)	N	

^aIncluding CK, CK5/6, CK7, CK19, and CK20.

^bIncluding chromogranin, CD56, and synaptophysin.

^cFor p53 and C-MYC, the results are categorized as negative (0%-10%), focal positive (10%-50%), and positive (>50%).

Abbreviations: EGFR, epidermal growth factor receptor; FISH, fluorescent in situ hybridization; IHC, immunohistochemistry; MEC, mucoepidermoid carcinoma; N, negative; n.a., not available; NC, NUT carcinoma; NE, neuroendocrine marker; No. number of patient; P, positive; PD-L1, programmed cell death ligand 1; SNUD, sinonasal undifferentiated carcinoma; SqCC, squamous cell carcinoma.

dose-dependent manner (Fig. 3A, 3B), with an $IC_{50} < 10$ nmol/L in the four NUT carcinoma cell lines (supplemental online Table 1). In particular, CUDC-907 most strongly inhibited the proliferation of NUT carcinoma cells, including SNU-2972-1 (6.2 ± 0.2 pmol/L), SNU-3178S (5.5 ± 0.2 pmol/L), Ty-82 (7.7 ± 0.2 pmol/L), and HCC2429 (9.0 ± 0.2 pmol/L) cells, with an IC_{50} of picomolar range. To understand the mechanism by which CUDC-907 exerts strong cytotoxicity in NUT carcinoma cells, we performed kinome-wide siRNA library screening of SNU-3178S and SNU-2972-1 cells. Among hits, we found that siRNA-mediated knockdown of *PIK3CA* resulted in a profound decrease in cell viability in both cell line models (supplemental online Fig. 2). Given that CUDC-907 is a potent inhibitor of PI3K as well as HDAC, inhibition of both molecules may underlie the exquisite sensitivity of NUT carcinoma cell lines to this compound.

DISCUSSION

Our study demonstrated that the clinicopathological features of 13 East Asian patients with NUT carcinoma, most (83%) of whom had stage IV disease, were similar to those of Western patients except for the longer median OS of 10.6 months in our series. In addition, local therapy seems important, as patients who were able to reach surgery had a better outcome. Kinome siRNA screening revealed *PIK3CA* as a shared positive hit; thus, CUDC-907, a dual HDAC and PI3K inhibitor, was potent against NUT carcinoma cell lines.

Although NUT carcinoma has a dismal outcome (median OS, 4.7-9.7 months), upfront and intensive local approaches, such as gross total resection and radiotherapy, may provide survival benefits (Table 3) [6-8, 10]. Similarly, our six patients who underwent upfront surgery survived significantly longer

than the others, and two of them with stage IV disease (NC2 and 3) survived for approximately 2 years. Although long-term remission in response to chemoradiotherapy without surgery was reported in two patients previously [10, 23], the benefit of chemotherapy or radiotherapy without surgery was unclear [8]. In our patients, the long-term survivor, NC3 underwent aggressive gross total resection, including metastasectomy plus chemoradiotherapy, which suggests the important role of local modalities in the treatment of advanced NUT carcinoma.

The head and neck and thorax regions were predilected sites for NUT carcinoma in our study, as in other studies (Table 3) [7, 10]. The median age of patients was 48.0 years, which was older than that reported previously (Table 3) [6-8, 10]. Because of its rarity and undifferentiated histology, NUT carcinoma is often misdiagnosed in 61.5% of cases in our series and 50%-66% of other cases as other tumors, including undifferentiated and poorly differentiated carcinoma, sinonasal undifferentiated carcinoma, and Ewing sarcoma/primary neuroectodermal tumor [8, 10, 24, 25]. In our archived head and/or neck carcinoma data set, 40% of tumors initially diagnosed as sinonasal undifferentiated carcinoma were subsequently diagnosed as NUT carcinoma [24, 25]. NUT carcinoma is known to be unrelated to oncogenic viruses, such as Epstein-Barr virus (EBV) and human papillomavirus (HPV), and tobacco consumption [25]. Therefore, considering the aggressive behavior of NUT carcinoma, IHC using a highly specific antibody against NUT should be performed in any cases of poorly differentiated carcinoma of the head and neck or lung, particularly in the absence of EBV and HPV. In addition, molecular assays including FISH for *NUT* translocation and reverse transcription polymerase chain reaction for *NUT* transcript would be useful for diagnosis [2, 3, 7, 9, 10, 22, 26].

In this study, NC7 showed focal positivity for NUT IHC despite *NUT* gene translocation. Because the FFPE block of

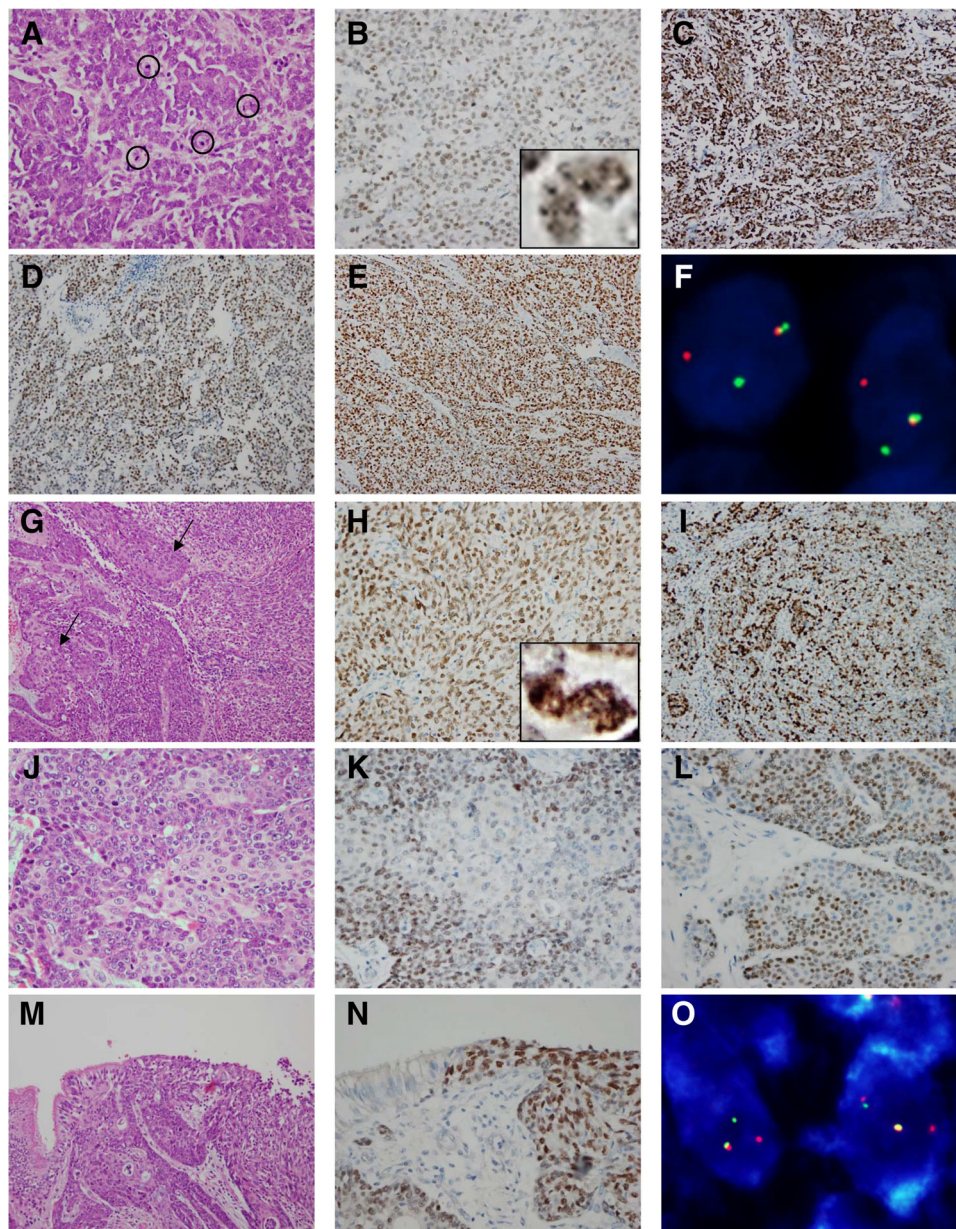


Figure 2. Pathological findings for NUT carcinoma (NC 3 and NC13. **(A)**: Loose nests of malignant cells show numerous mitotic figures in NC3. **(B–E)**: Immunohistochemistry of NC3 revealed that the tumor cells were positive for NUT, with a speckled pattern in the nuclei (insert) **(B)**, and diffusely positive for p53 **(C)**, C-MYC **(D)**, and p63 **(E)**. **(F)**: Translocation of the *NUT* gene is identified frequently in break-apart fluorescence in situ hybridization (FISH) in NC3. **(G)**: A sheet of poorly differentiated basaloid cells with abrupt squamous differentiation foci (arrows) in NC13. **(H)**: Immunohistochemistry of NC13 revealed that the tumor cells were positive for NUT, with a speckled pattern in the nuclei (insert), and **(I)** diffusely positive for p53. **(J)**: Foci of squamous differentiation with decreased expression levels of **(K)** NUT and **(L)** C-MYC were present in NC13. **(M)**: Tumor cells of NC13 were observed in the ciliated respiratory epithelium, **(N)** along with the abrupt transition of NUT expression. **(O)**: A FISH assay demonstrated *NUT* break apart and occasional triploidy with an isolated red signal in NC13.

NC7 was made 7 years previously, protein degradation may account for the focal positivity of NUT IHC. The *NUT* gene translocation pattern was simple in the FISH assay in all cases except NC13, which showed *NUT* gene gains with an isolated red signal in addition to paired green and red signals. Consistently, it was previously reported that chromosomal alterations underlying the simple *BRD4/BRD3-NUT* transcript can be highly sophisticated and even harbor hyperdiploidy [18].

In NC13, continuation of the normal bronchial epithelium and malignant cells was observed where the NUT-positive

cells showed an abrupt transition from NUT-negative cells in the epithelium (Fig. 2M–N). In a previous report on pulmonary NUT carcinoma [26], tumor cells adjacent to normal bronchial epithelium showed NUT and thyroid transcription factor-1 expression, suggesting a bronchial epithelial cell origin of pulmonary NUT carcinoma. Taken together, these findings suggest that *NUT* translocation is an initial event of NUT carcinoma oncogenesis.

IHC features for cytokeratin, p63, and neuroendocrine markers were comparable to those observed in previous studies

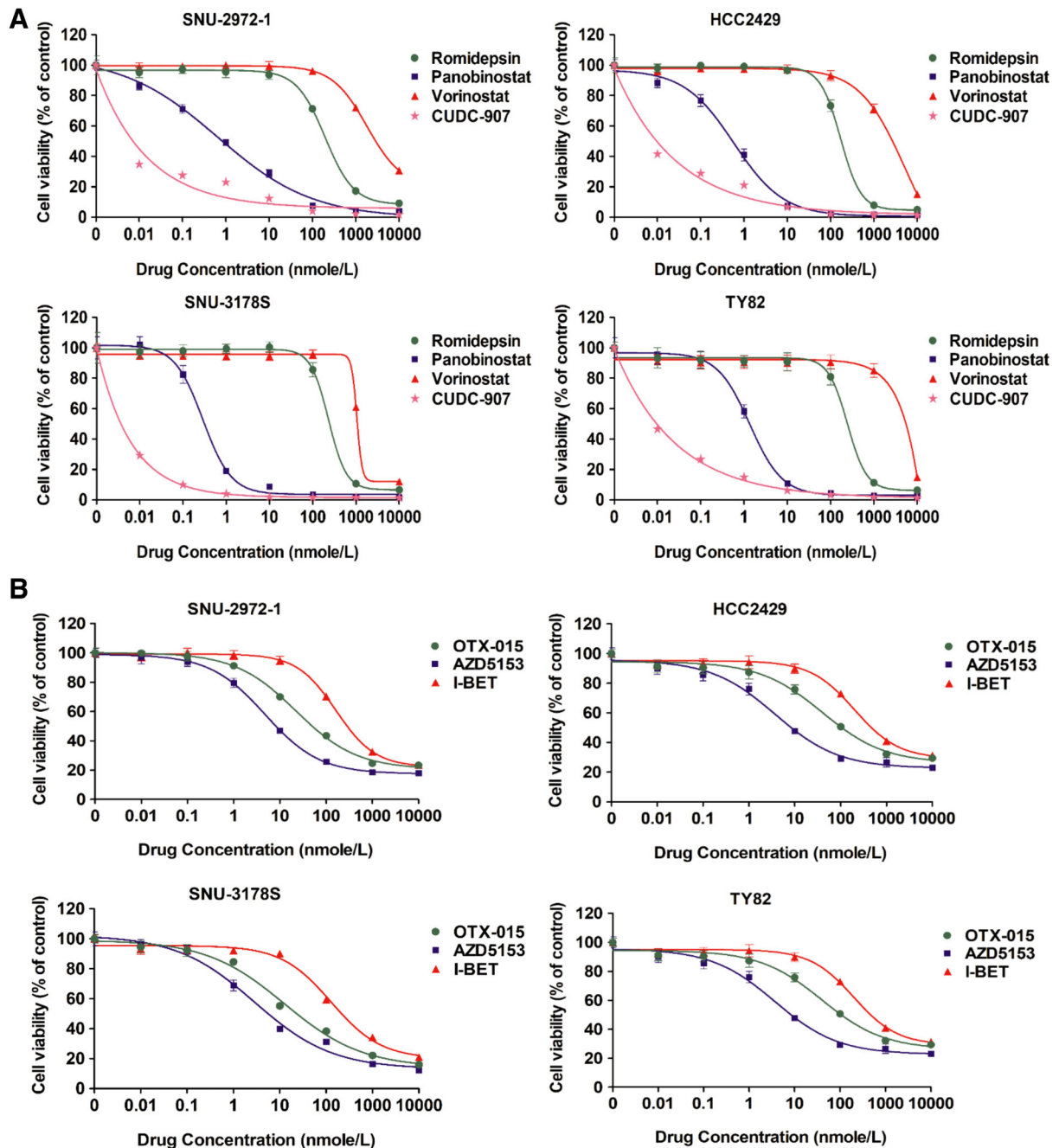


Figure 3. Cell viability assays for histone deacetylase (HDAC) and bromodomain and extraterminal (BET) inhibitors in NUT carcinoma (NC) cell lines. Proliferation assays for four NC cell lines treated with increasing doses of HDAC inhibitors (CUDC-907, panobinostat, vorinostat, and romidepsin) **(A)** and BET inhibitors (I-BET, OTX-015, and AZD5153) **(B)** from 0.01 nmol/L to 10,000 nmol/L for 72 h. Error bars represent the standard deviations of triplicate experiments.

[9, 24]. We observed high and frequent overexpression of p53 in NUT carcinoma cases. The reason for this finding is uncertain because chromosomal rearrangement or somatic mutation of p53 was not found in the SNU-2972-1 or SNU-317S cell line in our previous study [18]. p300 HAT is sequestered to the NUT moiety BRD4-NUT, which, in turn, acetylates p53 and binds it to the BRD4-NUT foci of the chromatin [13]. In addition, C-MYC is upregulated in NUT carcinoma by BRD4/BRD3-NUT, and it plays a key role in inhibiting differentiation and promoting the proliferation of NUT carcinoma cells [11, 14]. C-MYC expression was also observed frequently and

decreased in differentiated cells, consistent with a previous report [14]. Although a recent study demonstrated that BRD4 promoted PD-L1 expression, and that BET inhibitor enhanced cytotoxic T cell-dependent antitumor activity by repressing PD-L1 expression of tumor [27], PD-L1 expression was observed in only one patient (NC6) who underwent chemoradiotherapy in our study. Interestingly, EGFR and HER2 expression was observed in approximately 30% of NUT carcinoma cases, with no relevance of the differentiation status.

C-MYC-targeting agents, such as BET and HDAC inhibitors, disperses transcriptionally active chromatin domains and

Table 3. Demographic data and treatment outcomes from major NUT carcinoma studies

Demographic data	Bauer et al. [7]	Chau et al. [8]	Lemelle et al. [10]	Present study
Demographic findings				
Total (n)	63	48	12	13
Male/female	1.1	0.7	0.7	1.2
Median age, yr	16.0	21.9	18.1	48.0
Clinicopathological findings				
Primary sites	HN = 24, T = 35, other = 4	HN = 48	HN = 3, T = 6, other = 3	HN = 9, T = 4
Stage ^a	n.a.	n.a.	IV = 9, n.a. = 3	IV = 10, III = 1, II = 2
LN involvement (%)	40	26	75	46
Distant metastasis (%)	51	6	67	23
Treatment modality				
Upfront CT (%)	n.a.	28	≥50	25
Upfront surgery (%)	n.a.	56	≤17	50
Radiotherapy (%)	≥49	74	42	42
Survival outcomes				
Median OS, mo	6.7	9.7	4.7	10.6
Median PFS, mo	NA	6.6	1.9	4.4

^abased on AJCC cancer staging manual 7th edition.

Abbreviations: CT, chemotherapy; HN, head/neck; LN, regional lymph node; n.a., not available; OS, overall survival; PFS, progression-free survival; T, thorax.

restores global histone acetylation, respectively, which promote the differentiation of NUT carcinoma cells and shows clinical activities [15, 28]. Clinically, OTX015/MK-8628, a novel BET inhibitor targeting BRD2, BRD3, and BRD4, showed responses in two of four patients with NUT carcinoma through compassionate use [17]. AZD5153, which is a bivalent BET inhibitor unlike other monovalent BET inhibitors [29, 30], showed antitumor activity against NUT carcinoma cell lines, and it is on a phase I clinical trial for patients with relapsed and/or refractory solid tumors (NCT03205176). Regarding HDAC inhibitors, vorinostat showed responses in a short time because of significant adverse events in two cases [16, 31], whereas romidepsin was not effective in a 21-year-old patient with NUT carcinoma [32]. Considering that HDAC and PI3K inhibition synergistically reduces the C-MYC protein level and MYC transcription, CUDC-907, a dual HDAC/PI3K inhibitor, is potent against MYC-driven tumors, including the NUT carcinoma xenograft model [33]. These findings are comparable to those of our study, which demonstrated superior potency against NUT carcinoma cell lines and positive hit of *PIK3CA* by kinome siRNA screening. A phase I study of CUDC-907 (NCT02307240) has involved the recruitment of patients with advanced and/or relapsed NUT carcinoma in whom standard therapy failed. However, because of poor pharmacokinetic properties of hydroxamic acids that are rapidly cleared and have short half-lives, these exhibit limited efficacies in patients with solid tumors as compared with their active in vitro efficacies [34].

CONCLUSION

The clinicopathological findings of East Asian patients with NUT carcinoma were similar to those of Western patients

with NUT carcinoma and include aggressive behavior, a typical immunophenotype, and poor survival outcomes, except for one long-term survivor without evidence of disease who received aggressive local treatment. A dual HDAC and PI3K inhibitor showed potent antitumor activity against in vitro NUT carcinoma models.

ACKNOWLEDGMENTS

This study was supported by a grant from the Korea Health Technology R&D Project through the Korea Health Industry Development Institute, funded by the Ministry of Health & Welfare (Grant HI17C0828, to T.M.K.) and Seoul National University Invitation Program for Distinguished Scholar (to Y.K.J.), Republic of Korea.

AUTHOR CONTRIBUTIONS

Conception/design: Tae Min Kim, Yoon Kyung Jeon

Provision of study material or patients: Sun Och Yoon, Heae Sung Park, Soon Won Hong, Weon-Seo Park, Ji Eun Kim, Hyun Jik Kim, Hyoung Jin Kang

Collection and/or assembly of data: Minsun Jung, Soyeon Kim, June-Koo Lee, Joon Kim, Kyeong Cheon Jung, Dae Seog Heo, Tae Min Kim, Yoon Kyung Jeon

Data analysis and interpretation: Minsun Jung, Soyeon Kim, June-Koo Lee, Bhumsuk Keam, Dong-Wan Kim, Young Tae Kim, Tae Min Kim, Yoon Kyung Jeon

Manuscript writing: Minsun Jung, Soyeon Kim, Tae Min Kim, Yoon Kyung Jeon

Final approval of manuscript: Minsun Jung, Soyeon Kim, June-Koo Lee, Sun Och Yoon, Heae Sung Park, Soon Won Hong, Weon-Seo Park, Ji Eun Kim, Joon Kim, Bhumsuk Keam, Hyun Jik Kim, Hyoung Jin Kang, Dong-Wan Kim, Kyeong Cheon Jung, Young Tae Kim, Dae Seog Heo, Tae Min Kim, Yoon Kyung Jeon

DISCLOSURES

The authors indicated no financial relationships.

REFERENCES

1. Kubonishi I, Takehara N, Iwata J et al. Novel t(15;19)(q15;p13) chromosome abnormality in a thymic carcinoma. *Cancer Res* 1991;51:3327–3328.
2. French CA, Miyoshi I, Kubonishi I et al. BRD4-NUT fusion oncogene: A novel mechanism in aggressive carcinoma. *Cancer Res* 2003;63:304–307.
3. French CA, Ramirez CL, Kolmakova J et al. BRD-NUT oncoproteins: A family of closely related nuclear proteins that block epithelial differentiation and maintain the growth of carcinoma cells. *Oncogene* 2008;27:2237–2242.
4. French CA, Rahman S, Walsh EM et al. NSD3-NUT fusion oncoprotein in NUT midline carcinoma: Implications for a novel oncogenic mechanism. *Cancer Discov* 2014;4:928–941.
5. Alekseyenko AA, Walsh EM, Zee BM et al. Ectopic protein interactions within BRD4-chromatin complexes drive oncogenic megadomain formation in NUT midline carcinoma. *Proc Natl Acad Sci USA* 2017;114:E4184–E4192.
6. French CA, Kutok JL, Faquin WC et al. Midline carcinoma of children and young adults with NUT rearrangement. *J Clin Oncol* 2004;22:4135–4139.
7. Bauer DE, Mitchell CM, Strait KM et al. Clinicopathologic features and long-term outcomes of NUT midline carcinoma. *Clin Cancer Res* 2012;18:5773–5779.
8. Chau NG, Hurwitz S, Mitchell CM et al. Intensive treatment and survival outcomes in NUT midline carcinoma of the head and neck. *Cancer* 2016;122:3632–3640.
9. Stelow EB. A review of NUT midline carcinoma. *Head Neck Pathol* 2011;5:31–35.
10. Lemelle L, Pierron G, Fréneau P et al. NUT carcinoma in children and adults: A multicenter retrospective study. *Pediatr Blood Cancer* 2017;64:e26693.
11. Alekseyenko AA, Walsh EM, Wang X et al. The oncogenic BRD4-NUT chromatin regulator drives aberrant transcription within large topological domains. *Genes Dev* 2015;29:1507–1523.
12. Filippakopoulos P, Qi J, Picaud S et al. Selective inhibition of BET bromodomains. *Nature* 2010;468:1067–1073.
13. Reynold N, Schwartz BE, Delvecchio M et al. Oncogenesis by sequestration of CBP/p300 in transcriptionally inactive hyperacetylated chromatin domains. *EMBO J* 2010;29:2943–2952.
14. Grayson AR, Walsh EM, Cameron MJ et al. MYC, a downstream target of BRD-NUT, is necessary and sufficient for the blockade of differentiation in NUT midline carcinoma. *Oncogene* 2014;33:1736–1742.
15. Delmore JE, Issa GC, Lemieux ME et al. BET bromodomain inhibition as a therapeutic strategy to target c-Myc. *Cell* 2011;146:904–917.
16. Schwartz BE, Hofer MD, Lemieux ME et al. Differentiation of NUT midline carcinoma by epigenomic reprogramming. *Cancer Res* 2011;71:2686–2696.
17. Stathis A, Zucca E, Bekradda M et al. Clinical response of carcinomas harboring the BRD4-NUT oncoprotein to the targeted bromodomain inhibitor OTX015/MK-8628. *Cancer Discov* 2016;6:492–500.
18. Lee JK, Louzada S, An Y et al. Complex chromosomal rearrangements by single catastrophic pathogenesis in NUT midline carcinoma. *Ann Oncol* 2017;28:890–897.
19. Cho Y, Keam BS, Jung KC et al. A case of nuclear protein in testis midline carcinoma arising from the submandibular gland duct in a pregnant patient. *J Oral Maxillofac Surg* 2017;75:2020–2024.
20. Park HS, Bae YS, Yoon SO et al. Usefulness of nuclear protein in testis (NUT) immunohistochemistry in the cytodagnosis of NUT midline carcinoma: A brief case report. *Korean J Pathol* 2014;48:335–338.
21. Eisenhauer EA, Therasse P, Bogaerts J et al. New response evaluation criteria in solid tumours: Revised RECIST guideline (version 1.1). *Eur J Cancer* 2009;45:228–247.
22. Haack H, Johnson LA, Fry CJ et al. Diagnosis of NUT midline carcinoma using a NUT-specific monoclonal antibody. *Am J Surg Pathol* 2009;33:984–991.
23. Mertens F, Wiebe T, Adlercreutz C et al. Successful treatment of a child with t(15;19)-positive tumor. *Pediatr Blood Cancer* 2007;49:1015–1017.
24. Bishop JA, Westra WH. NUT midline carcinomas of the sinonasal tract. *Am J Surg Pathol* 2012;36:1216–1221.
25. Stelow EB, Bellizzi AM, Taneja K et al. NUT rearrangement in undifferentiated carcinomas of the upper aerodigestive tract. *Am J Surg Pathol* 2008;32:828–834.
26. Tanaka M, Kato K, Gomi K et al. NUT midline carcinoma: Report of 2 cases suggestive of pulmonary origin. *Am J Surg Pathol* 2012;36:381–388.
27. Zhu H, Bengsch F, Svoronos N et al. BET bromodomain inhibition promotes anti-tumor immunity by suppressing PD-L1 expression. *Cell Rep* 2016;16:2829–2837.
28. French CA. Pathogenesis of NUT midline carcinoma. *Annu Rev Pathol* 2012;7:247–265.
29. Rhyasen GW, Hattersley MM, Yao Y et al. AZD5153: A novel bivalent BET bromodomain inhibitor highly active against hematologic malignancies. *Mol Cancer Ther* 2016;15:2563–2574.
30. Bradbury RH, Callis R, Carr GR et al. Optimization of a series of bivalent triazolopyridazine based bromodomain and extraterminal inhibitors: The discovery of (3R)-4-[2-[4-[1-(3-methoxy-[1,2,4]triazolo[4,3-b]pyridazin-6-yl)-4-piperidyl]phenoxy]ethyl]-1,3-dimethyl-piperazin-2-one (AZD5153). *J Med Chem* 2016;59:7801–7817.
31. Maher OM, Christensen AM, Yedururi S et al. Histone deacetylase inhibitor for NUT midline carcinoma. *Pediatr Blood Cancer* 2015;62:715–717.
32. Maur M, Toss A, Dominici M et al. Impressive response to dose-dense chemotherapy in a patient with NUT midline carcinoma. *Am J Case Rep* 2015;16:424–429.
33. Sun K, Atoyan R, Borek MA et al. Dual HDAC and PI3K inhibitor CUDC-907 downregulates MYC and suppresses growth of MYC-dependent cancers. *Mol Cancer Ther* 2017;16:285–299.
34. McClure JJ, Li X, Chou CJ. Advances and challenges of HDAC inhibitors in cancer therapeutics. *Adv Cancer Res* 2018;138:183–211.



See <http://www.TheOncologist.com> for supplemental material available online.